

Do I Need a Helmet?

Management of Abnormal Head Shapes

Sameer Shakir, MD¹ and Irene Kim, MD²

¹Division of Pediatric Plastic Surgery

²Division of Pediatric Neurosurgery



Children's Specialty Group

Disclosures

- I have no relevant financial disclosures

Outline

- Head Shape and Growth
- Craniosynostosis
- Positional/Deformational Plagiocephaly
- New Head Shape Program



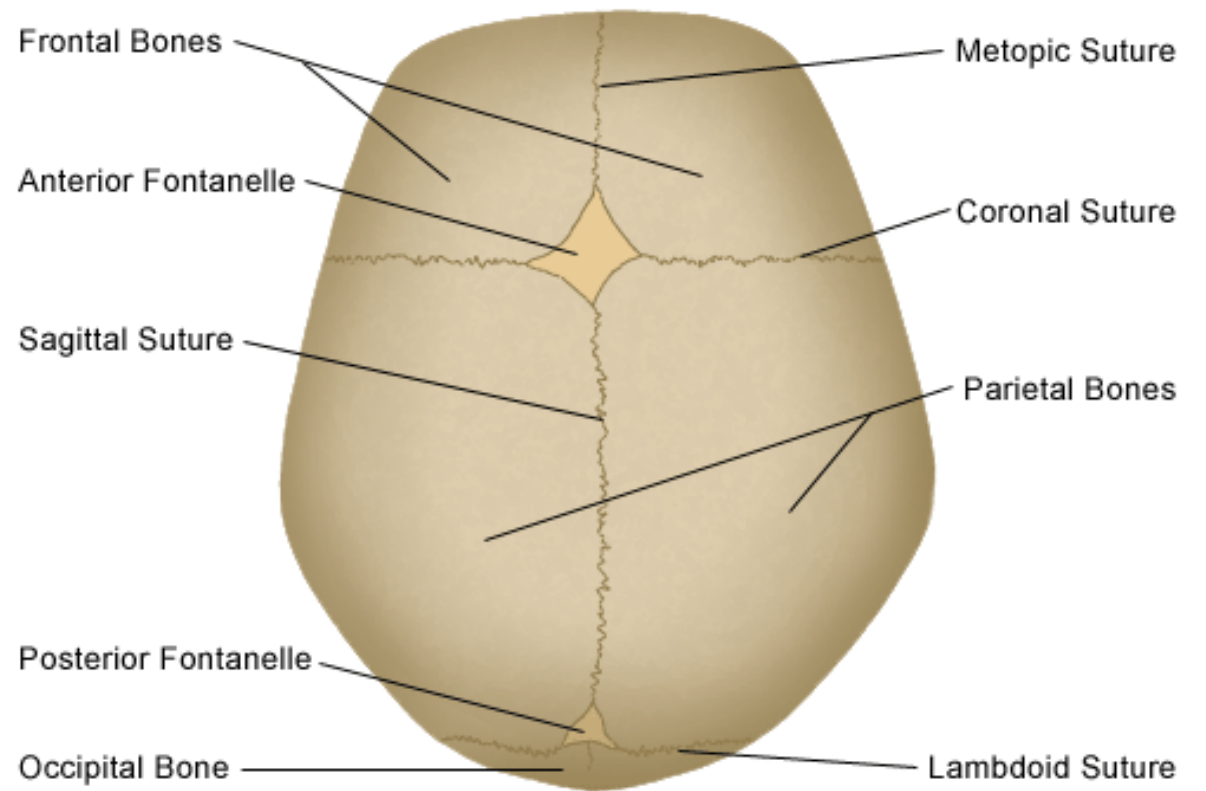
Children's
Wisconsin



Children's Specialty Group

The Normal Newborn Skull

- Multiple bones separated by sutures
- Major sutures
 - Metopic
 - Sagittal
 - Coronal (x2)
 - Lambdoid (x2)
- Anterior Fontanelle
 - Junction of frontal and parietal bones
- Posterior Fontanelle
 - Junction of parietal and occipital bones



Normal Head Growth

- Driven by underlying brain growth
 - Virchow's Law, 1851
- Anterior Fontanelle
 - Normal closure: 3 months to >2 years
 - 5% closed at 5 months
 - 90% closed at 24 months
- Fontanelle size does not correlate with timing of closure

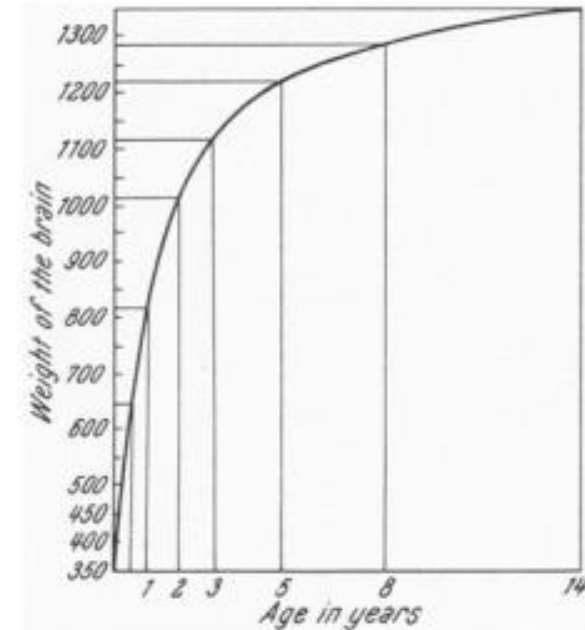
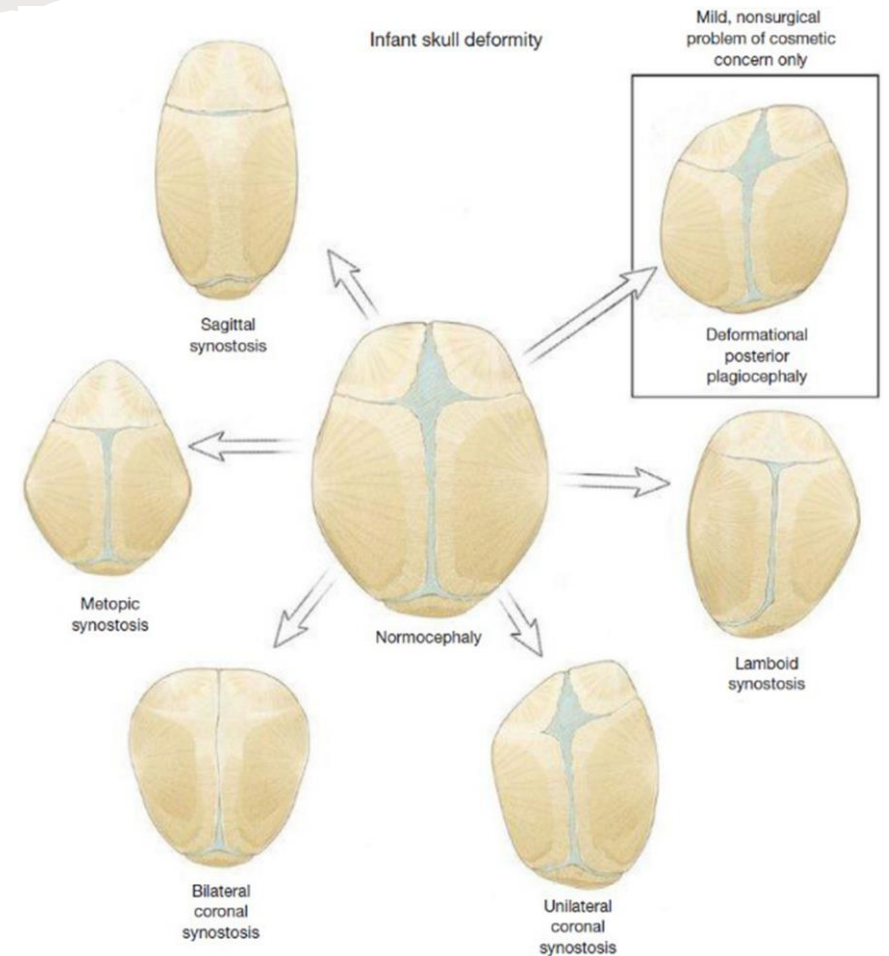


Fig. 1. Relationship between age and weight of brain (after Tod et al. 1971)

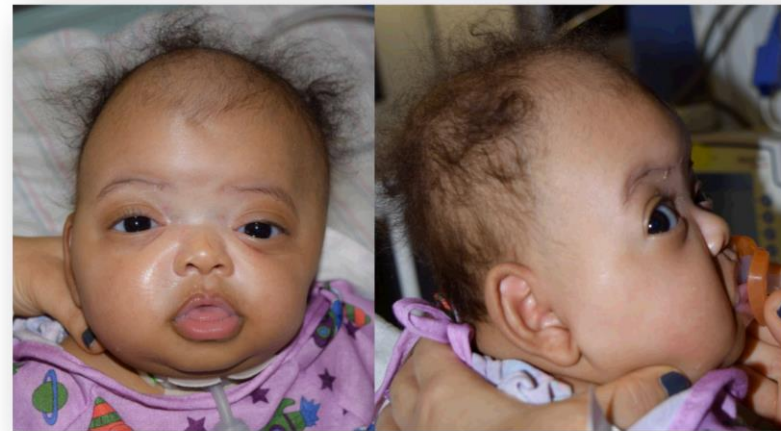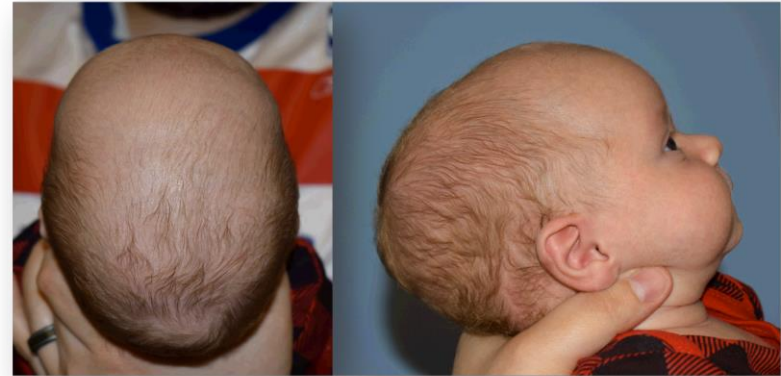Abnormal Head Shape

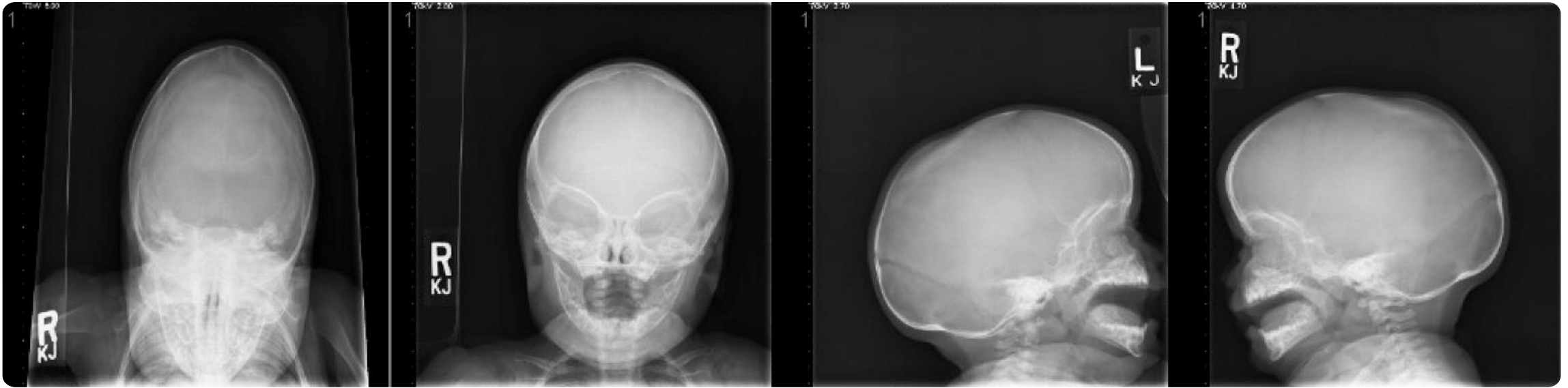
- Craniosynostosis
 - Premature closure of 1+ sutures
- Plagiocephaly
 - Posterior flattening due to external forces on growing skull
 - AKA deformational or positional plagiocephaly



Craniosynostosis

- 1 in 2,000-2,500
- Most occur in isolation
- 10-20% syndromic
 - Mutations in *FGFR* and *TWIST* genes
 - Often includes at least bicoronal craniosynostosis
 - 150+ syndromes
 - Crouzon syndrome (*FGFR2*)
 - Apert syndrome (*FGFR2*)
 - Pfeiffer syndrome (*FGFR2* and *FGFR1*)
 - Muenke syndrome (*FGFR3*)
 - Saethre-Chotzen (*TWIST1*)





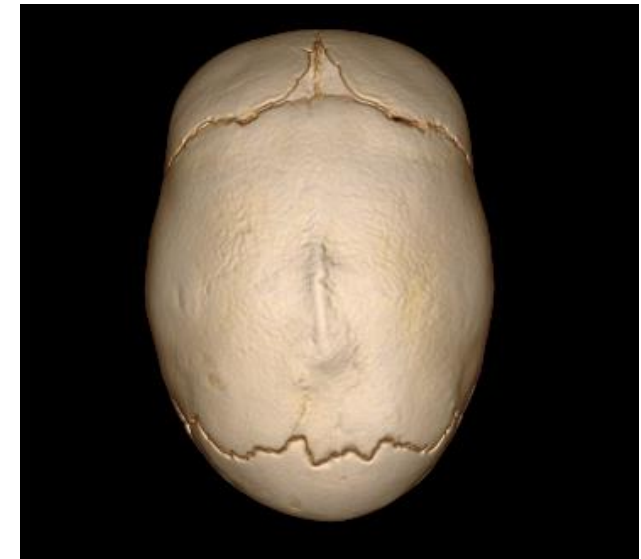
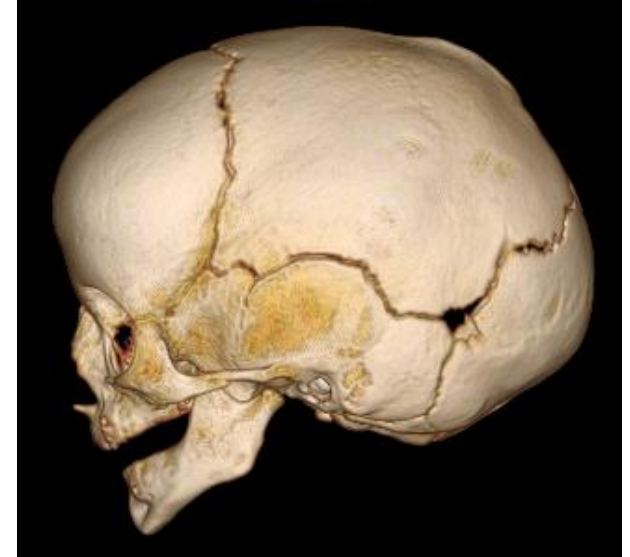Diagnosis

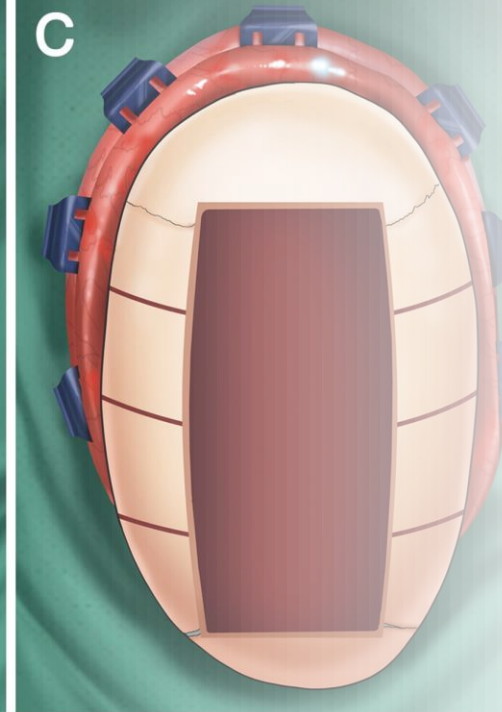
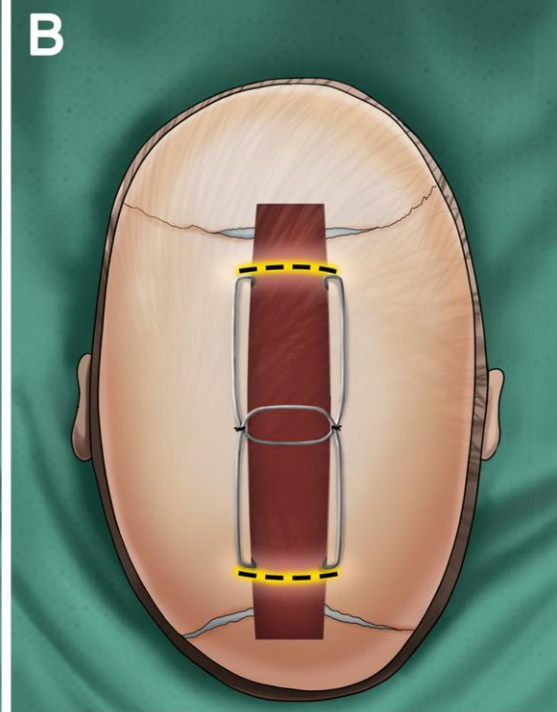
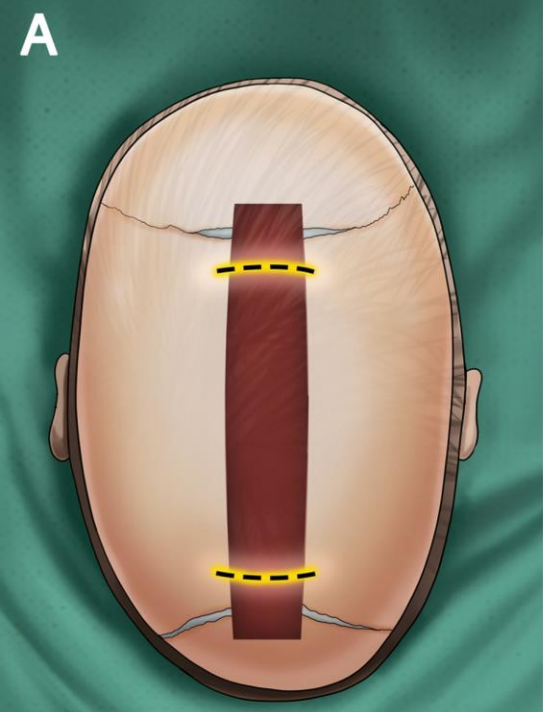
- Can usually be made on physical exam
- Consider skull XR if unclear (Townes View)
- Defer CT for diagnostic purposes
 - Surgical planning closer to time of surgery
 - Avoid unnecessary radiation



Sagittal Craniosynostosis

- Most common—40-45%
- Male > Female ~3.5 to 1
- No (historical) genetic cause (TWIST1?, 2-10% familial), multifactorial etiology
- Examination
 - Scaphocephaly—long, narrow
 - Ridging along sagittal suture
 - Bifrontal bossing
 - Bitemporal narrowing
 - Occipital constriction


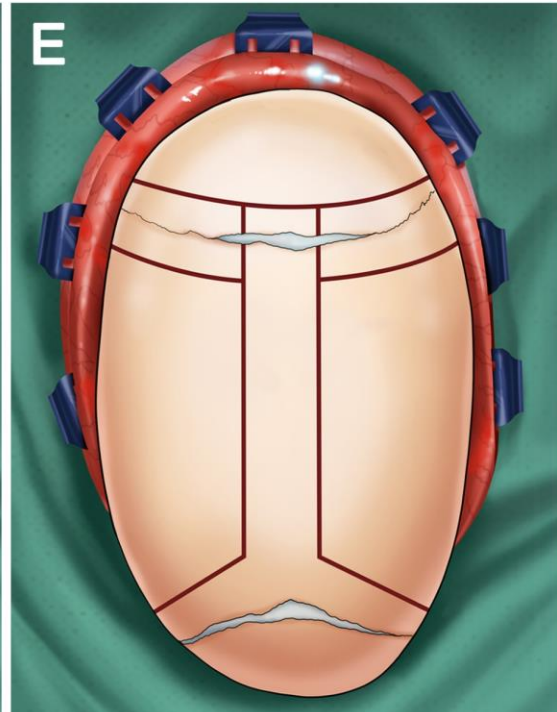
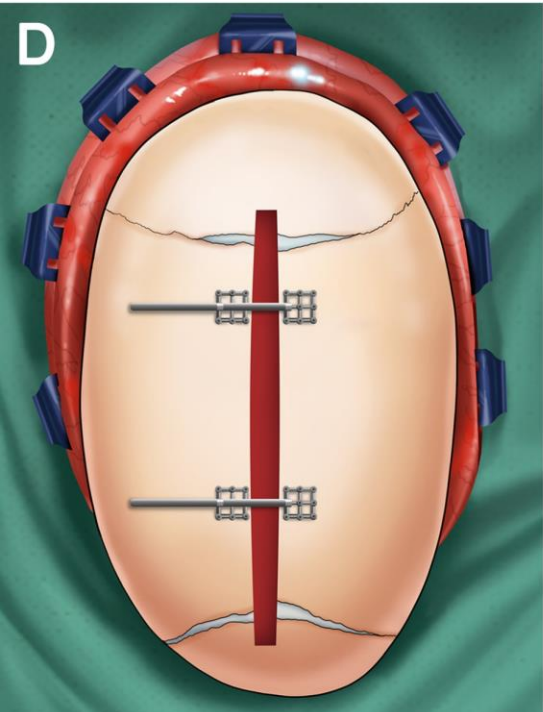




Surgical Management

- Reconstruction is an age-dependent approach
 - Early diagnosis is critical

- Treatment modalities

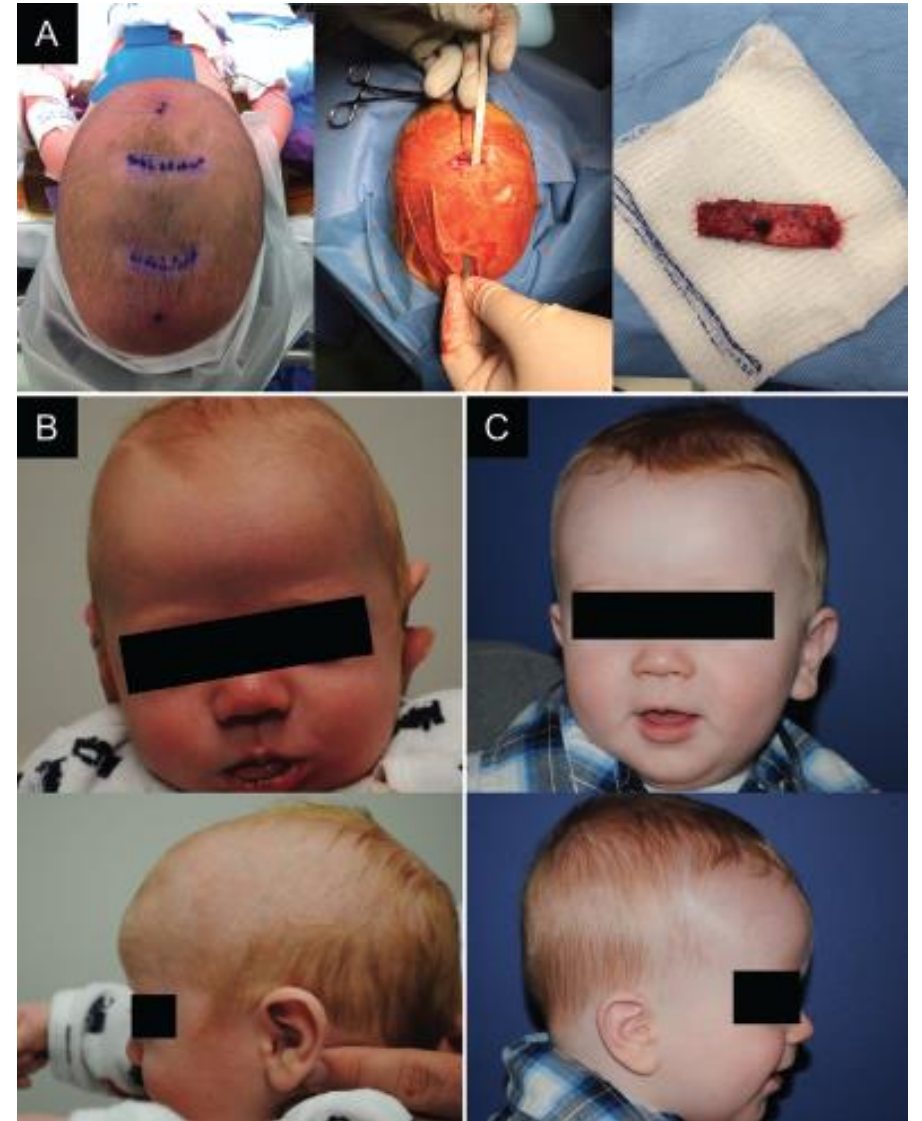


- “minimally invasive” strip craniectomy followed by helmet therapy
- Spring-mediated cranioplasty
- Open cranial vault remodeling

- **No compelling data to suggest that minimally invasive or open surgery for sagittal craniosynostosis is superior with respect to cosmesis or neurodevelopment**

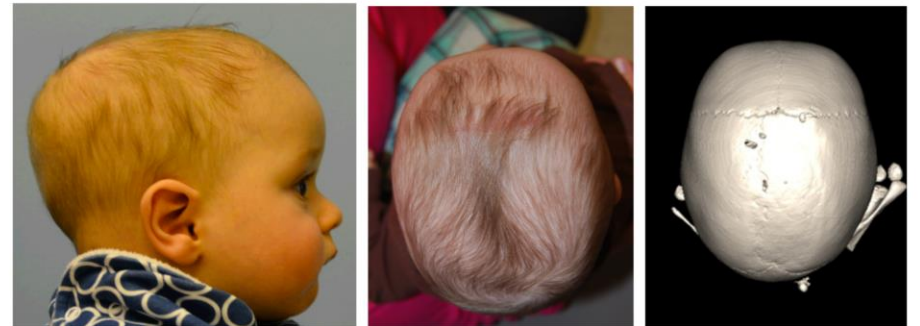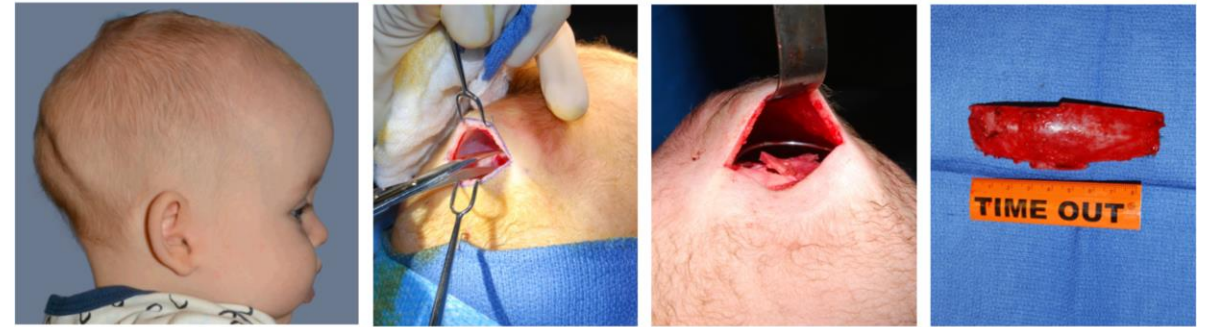
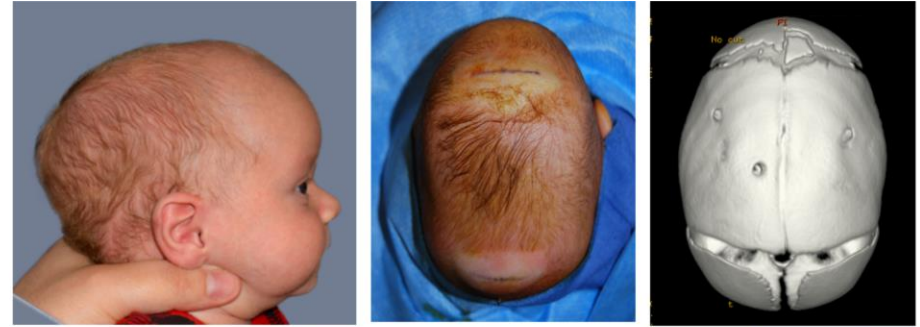Minimally Invasive Strip Craniectomy

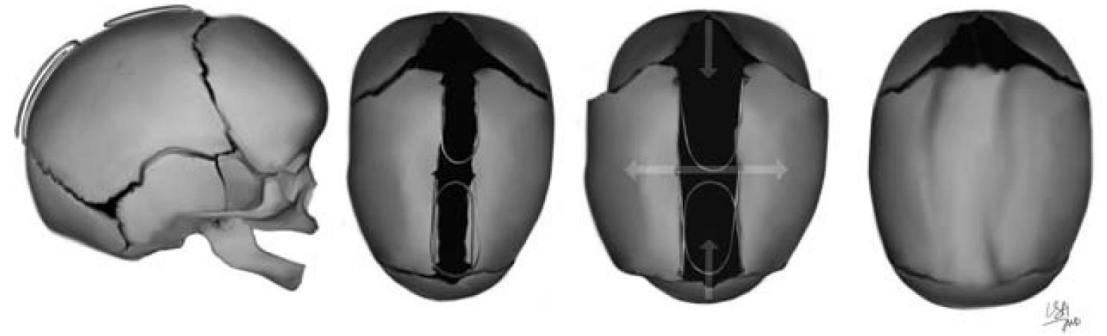
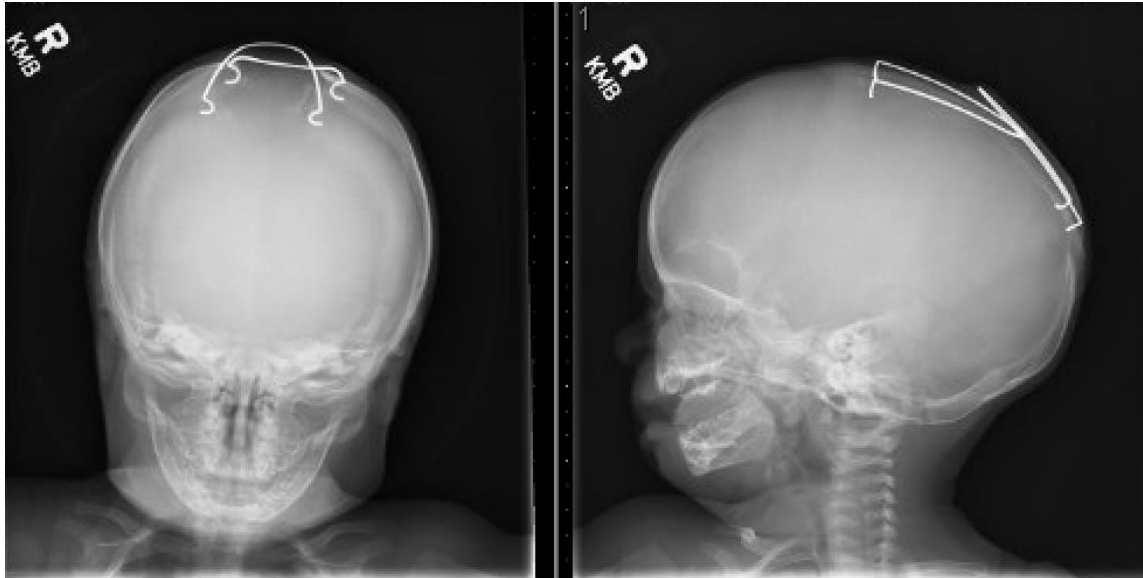
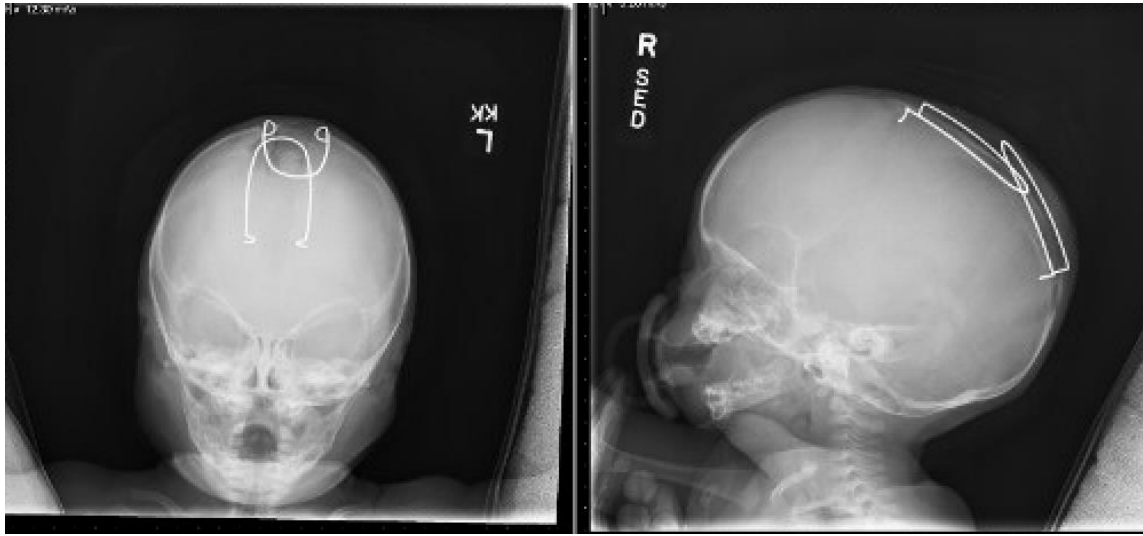
- AKA endoscopic strip craniectomy
- Performed before 3 months of age
- Requires helmet therapy postoperatively to correct head shape
 - 23 hours daily for 8-12 months



Spring-Mediated Cranioplasty

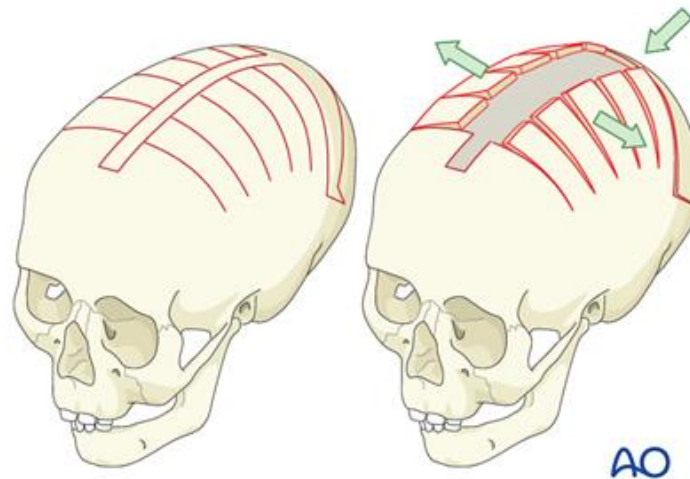
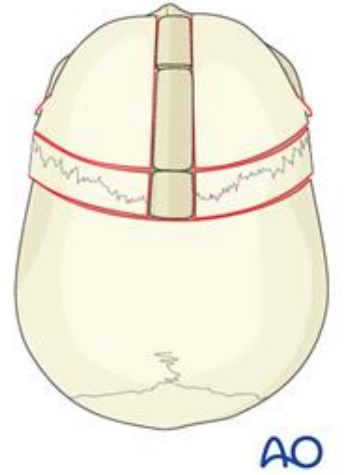
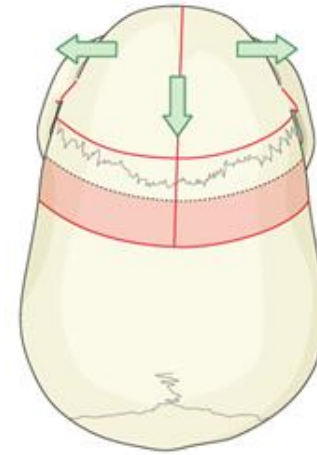
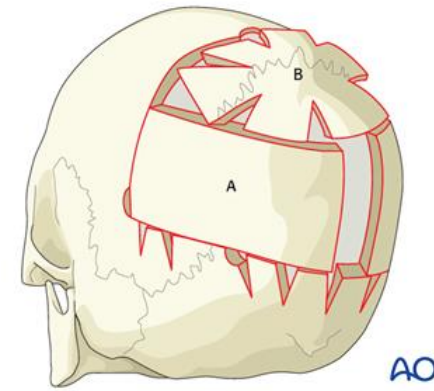
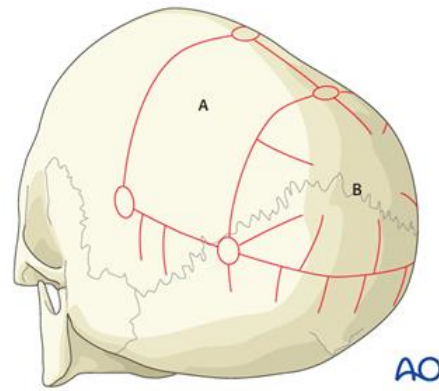
- Narrow strip craniectomy with placement of spring distractors
- Performed between 3-6 months of age
- Day surgery to remove springs 3-4 months later
- No helmet required
- Started offering at Children's Wisconsin in fall 2022





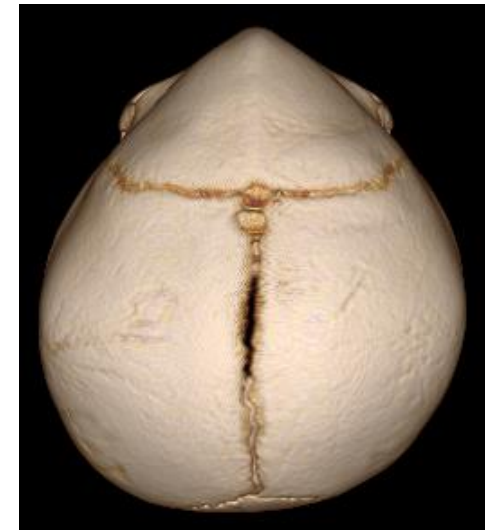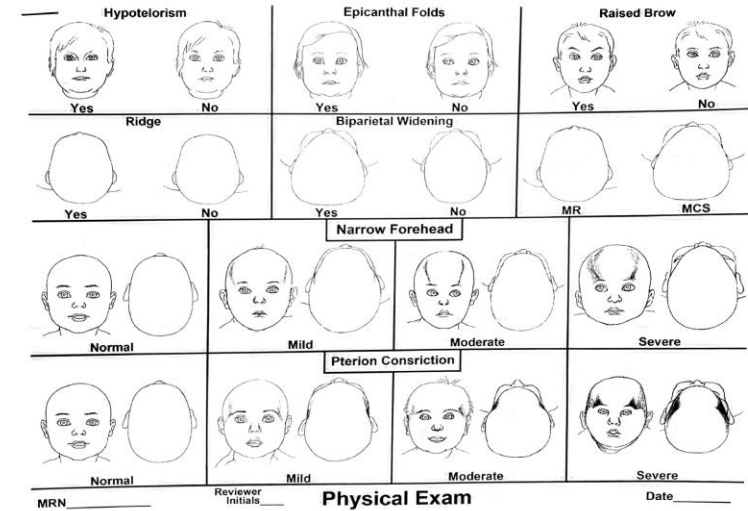
Cranial Vault Remodeling

- Multiple different surgical techniques
- Performed >4 months of age
- Longer surgery
 - Larger incision
 - More blood loss
- “One and Done”—
Immediate head shape correction



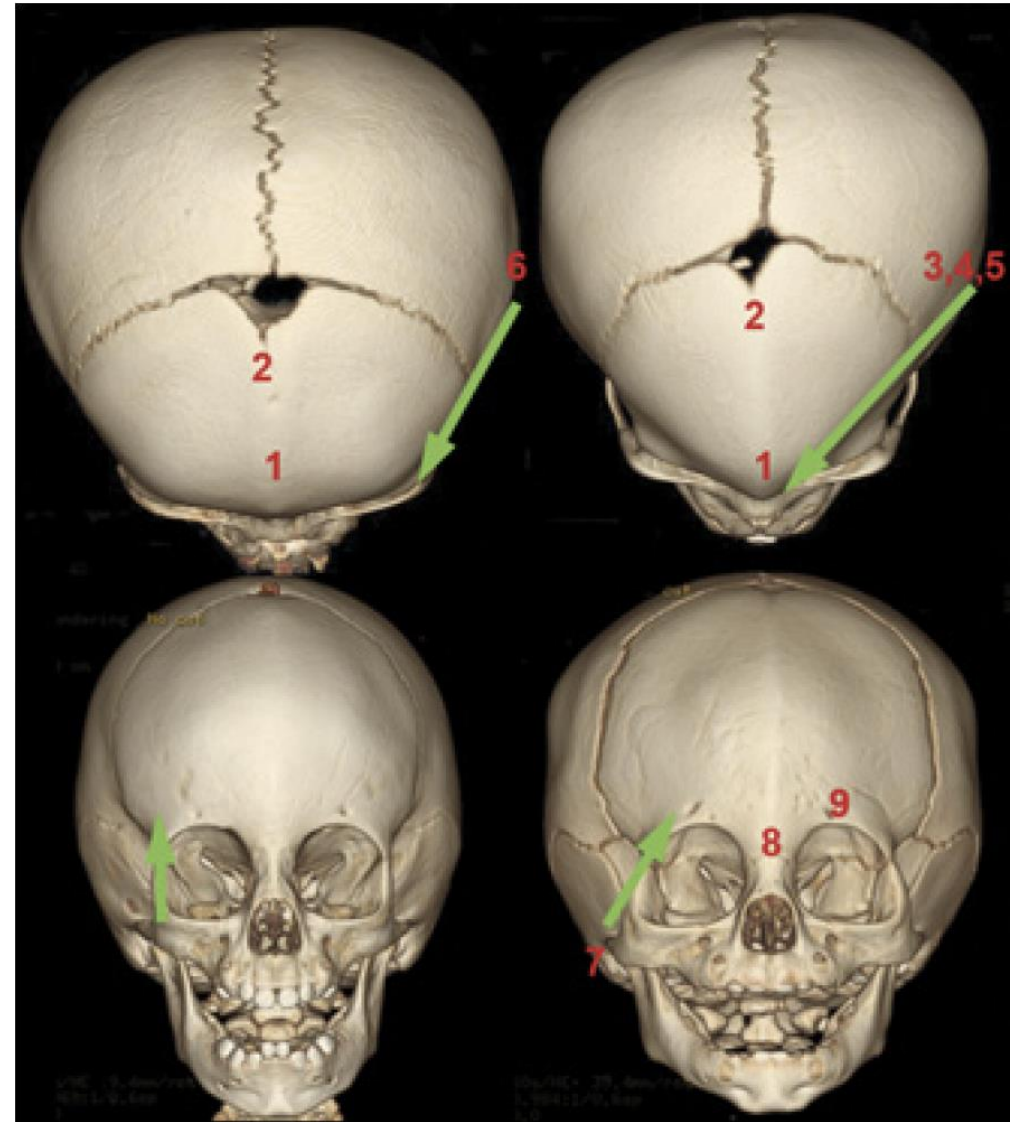
Metopic Craniosynostosis

- Second most common—19% to 28% of all cases
- Male > female 1.8-2.8 to 1
- Examination
 - Trigonocephaly
 - Ridging along metopic suture
 - Hypotelorism
 - Bitemporal narrowing
 - Anterior fontanelle often closed



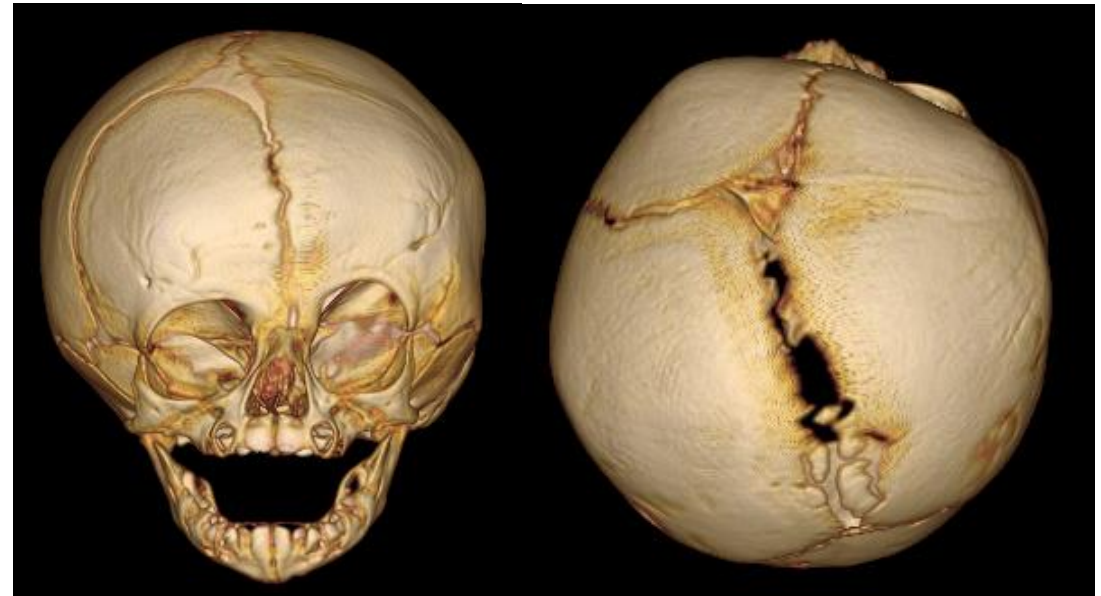Metopic Ridge

- Only suture to close in infancy
 - ~6-9 months
- Benign ridging along the suture as it closes
 - Will remodel
- No surgical intervention needed if no/minimal trigonocephaly



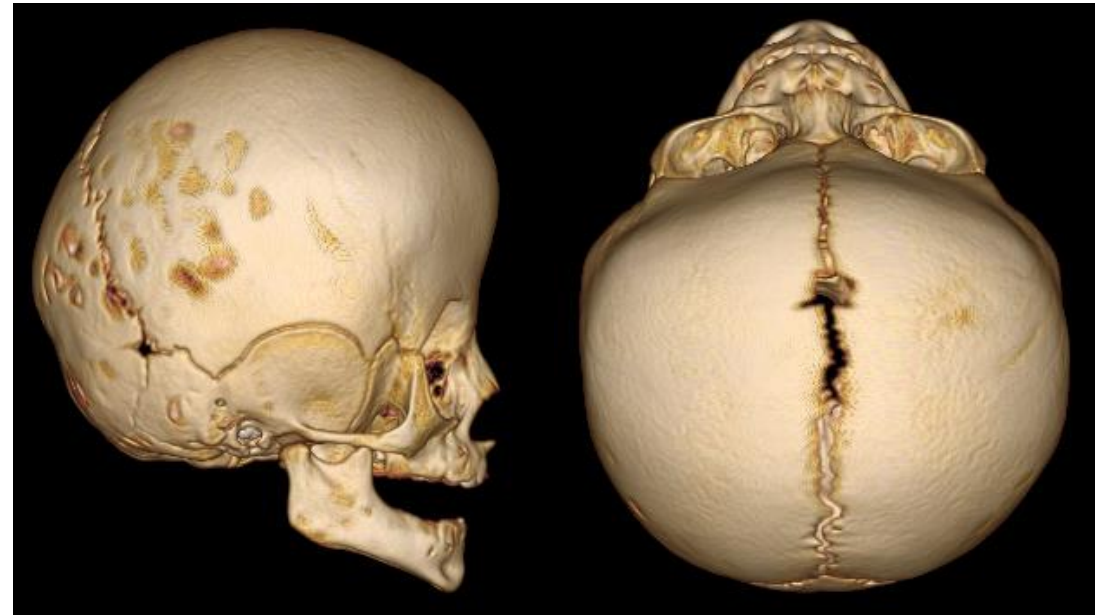Unicoronal Craniosynostosis

- Third most common
- Female > Male 1.6-3.6 to 1
- Examination
 - Forehead asymmetry
 - Flattening on ipsilateral side
 - Frontal bossing on contralateral side
 - Suture ridging
 - Harlequin deformity
 - Nasal root deviation
 - Strabismus
 - Anterior fontanelle often closed



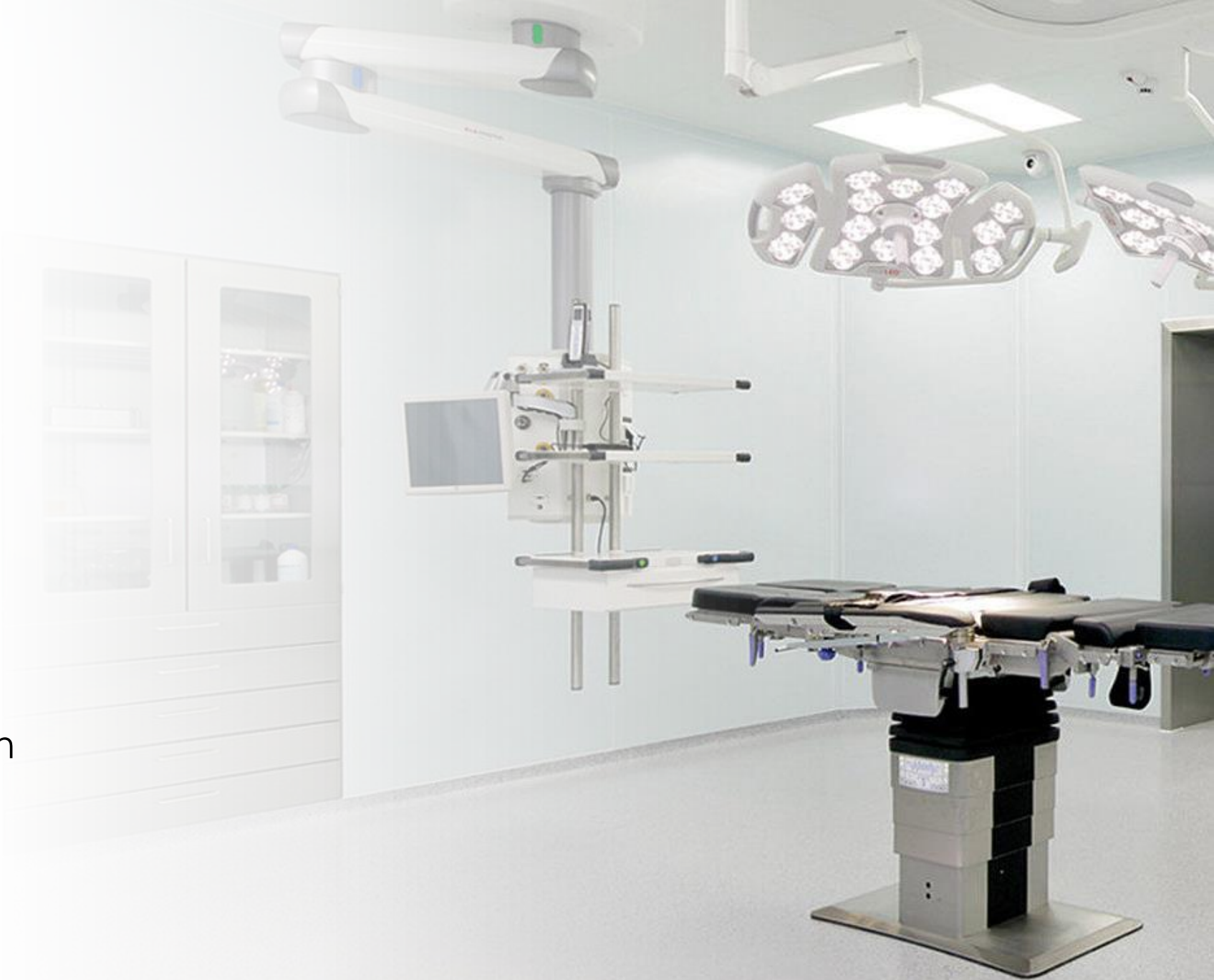Bicoronal Craniosynostosis

- In isolation or part of syndrome
- Examination
 - Brachycephaly
 - Turricephaly
 - Exophthalmos
 - Orbital and midface recession of
- May require staged surgery



Surgical Management

- Rarely urgent/emergent
- Indications
 - Head shape correction (aesthetic)
 - Prevent intracranial hypertension—ensure adequate room for brain growth
 - ~15-20%, single suture
 - ~60%, multisuture

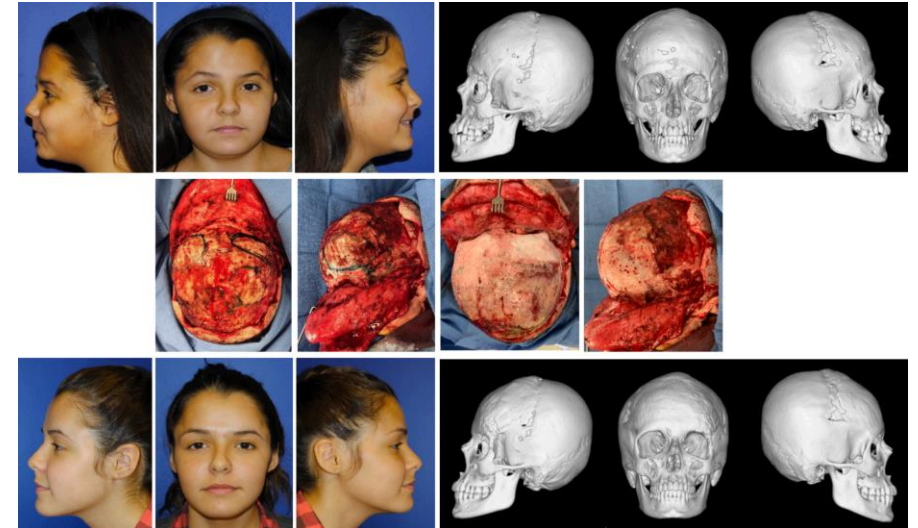


Surgical Management

- Options depend on type of craniosynostosis and age
 - Minimally/Less invasive versus open
 - Different types of open repair
 - Conventional versus distraction
 - Anterior versus posterior
- **Most patients with single suture craniosynostosis will require a single surgery during infancy**

Surgical Management

- Continued surveillance for delayed intracranial hypertension and aesthetic concerns
 - Infrequent secondary cranial vault EXPANSION
 - More common with multisuture
- If delayed diagnosis (>2-3 years of age)
 - Some will require surgery
 - Some will be managed conservatively with close observation



Neurocognitive Outcomes

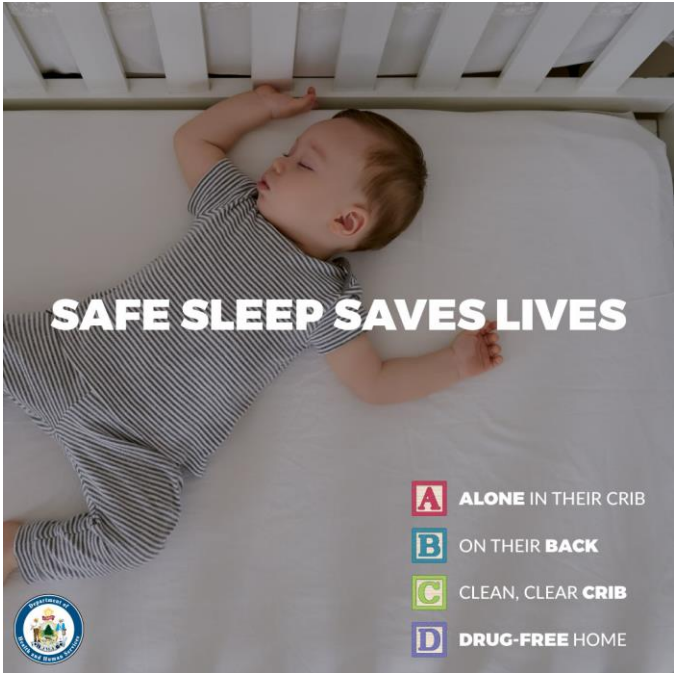- 3-5x increased rates of delays in 35-50% of patients
- Early → mental and psychomotor
- School age → language acquisition

- **Surgery does not clearly alter the path of ongoing delay**
 - **Main indication = head shape correction**



Positional Plagiocephaly

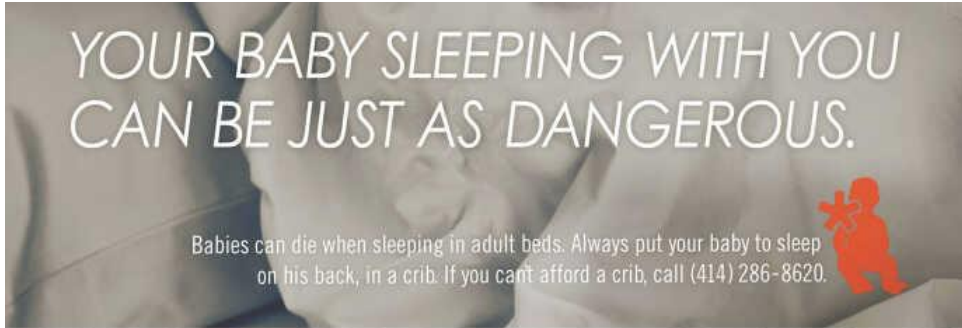AKA Deformational Plagiocephaly



SAFE SLEEP SAVES LIVES



- A** ALONE IN THEIR CRIB
- B** ON THEIR BACK
- C** CLEAN, CLEAR CRIB
- D** DRUG-FREE HOME



YOUR BABY SLEEPING WITH YOU CAN BE JUST AS DANGEROUS.

Babies can die when sleeping in adult beds. Always put your baby to sleep on his back, in a crib. If you can't afford a crib, call (414) 286-8620.



CITY OF MILWAUKEE
HEALTH DEPARTMENT



Safe Sleep for Your Baby

Each year in the United States, thousands of babies die suddenly and unexpectedly. Some of these deaths result from **Sudden Infant Death Syndrome (SIDS)** and other sleep-related causes of infant death, such as suffocation.



Since the 1990s, when the U.S. back-sleeping recommendations were first released and public awareness efforts began, the overall U.S. SIDS rate has dropped.

But, as SIDS rates have declined, deaths from other sleep-related causes, such as suffocation, have increased, and certain groups remain at higher risk for SIDS than others.

For example, African American and American Indian/Alaska Native babies are at higher risk for SIDS than white, Hispanic, or Asian/Pacific Islander babies.

Safe Sleep Environment

To reduce the risk of SIDS and other sleep-related causes of infant death:



Always place baby on his or her back to sleep, for naps and at night.



Share your room with baby. Keep baby close to your bed, on a separate surface designed for infants.



Use a firm and flat sleep surface, such as a mattress in a safety-approved crib*, covered by a fitted sheet with no other bedding or soft items in the sleep area.



Breastfeeding reduces the risk of SIDS

Babies who are breastfed or are fed expressed breastmilk are at lower risk for SIDS compared with babies who were never fed breastmilk. According to research, the longer you exclusively breastfeed your baby (meaning not supplementing with formula), the lower his or her risk of SIDS.

If you bring baby into your bed for feeding, remove all soft items and bedding from the area. When finished, put baby back in a separate sleep area made for infants.

If you fall asleep while feeding baby in your bed, place him or her back in the separate sleep area as soon as you wake up.



* A crib, bassinet, portable crib, or play yard that follows the safety standards of the Consumer Product Safety Commission (CPSC) is recommended. For information on crib safety, contact the CPSC at 1-800-638-2772 or <http://www.cpsc.gov>.



Learn more about SIDS and safe infant sleep:
<http://safetosleep.nichd.nih.gov>

Positional Plagiocephaly (and Brachycephaly)

- Plagiocephaly
 - Flattening of one side of the back of the head
 - Uneven appearance to the head
 - Can affect facial symmetry
- Brachycephaly
 - Both sides of the back of the head are flat
- Most common head shape abnormalities
 - **20-50%** of 6-month-old infants
- Flattening of skull due to persistent external forces in utero and/or post-natally
 - ~80% acquired during the first 4-12 weeks of life
 - ~20% noted at birth
- All sutures are open/patent

Who is at risk?

- Intrauterine factors—due to relative fetal restraint
 - Primiparity
 - Multiple gestation
 - Oligohydramnios
- Post-natal factors
 - Torticollis—15-20%
 - **Prematurity**—prolonged supine positioning at early age / NICU stay
 - Congenital anomalies—prolonged supine position in infancy
 - Developmental delay

Diagnosis

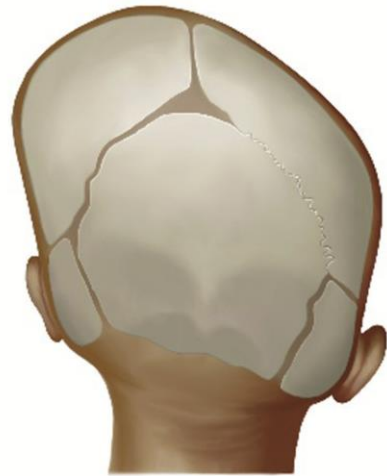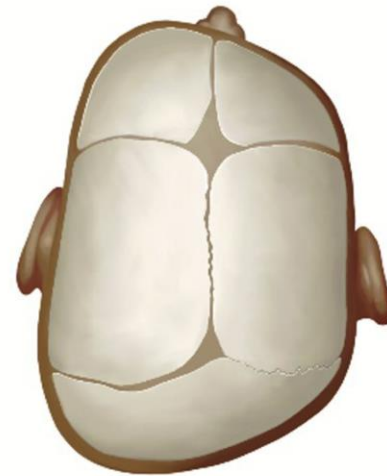
- Physical exam
 - Consider skull XR if unclear
- Deformational plagiocephaly—flattening on one side
 - DDX—lambdoid craniosynostosis (rarest type—incidence 1 in 40,000)
- Deformational brachycephaly—flattening on both sides
 - DDX—bicoronal craniosynostosis (also quite rare)



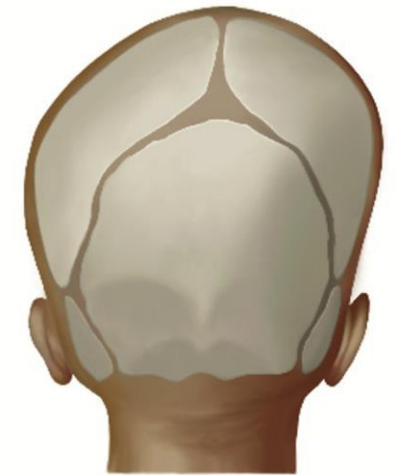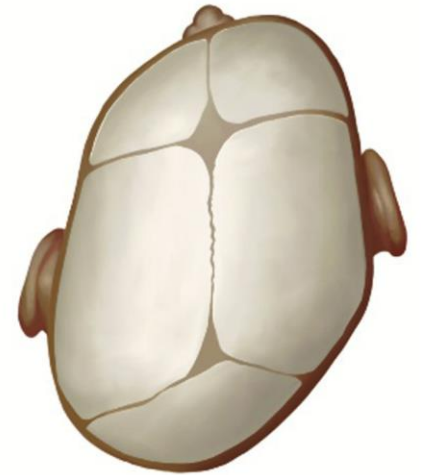
Well, what is it?

- Probably deformational plagiocephaly
 - Parallelogram
 - NOT trapezoid
 - **Ipsilateral ear anterior**
 - Ipsilateral forehead anterior
 - No mastoid bulge or cranial base tilt

Lambdoid Synostosis



Positional Plagiocephaly



Geometric controversy

- **Ipsilateral mastoid bossing, skull base cant, and inferior ear deviation** clinically correlates with suture fusion
- Trapezoid head shape and posterior ear deviation do not

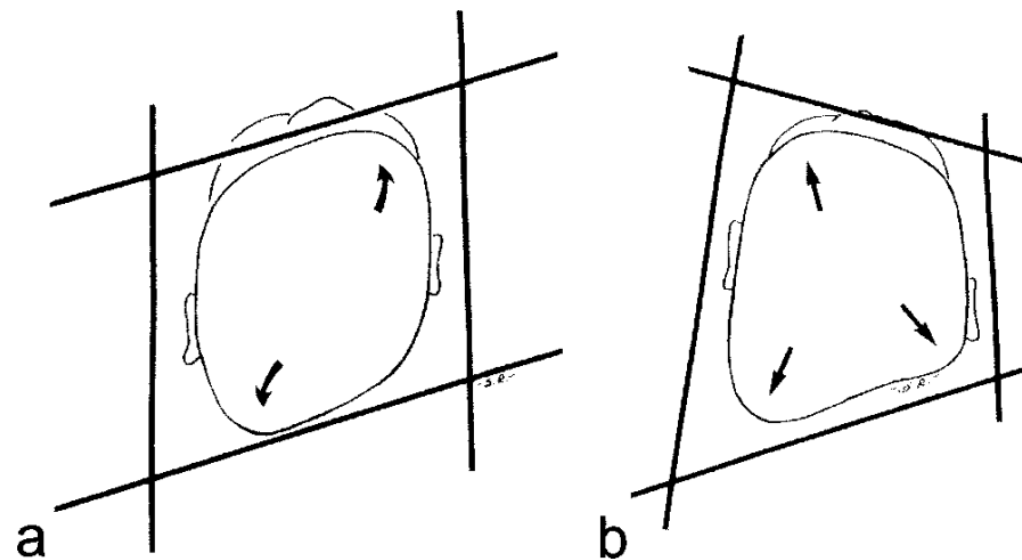


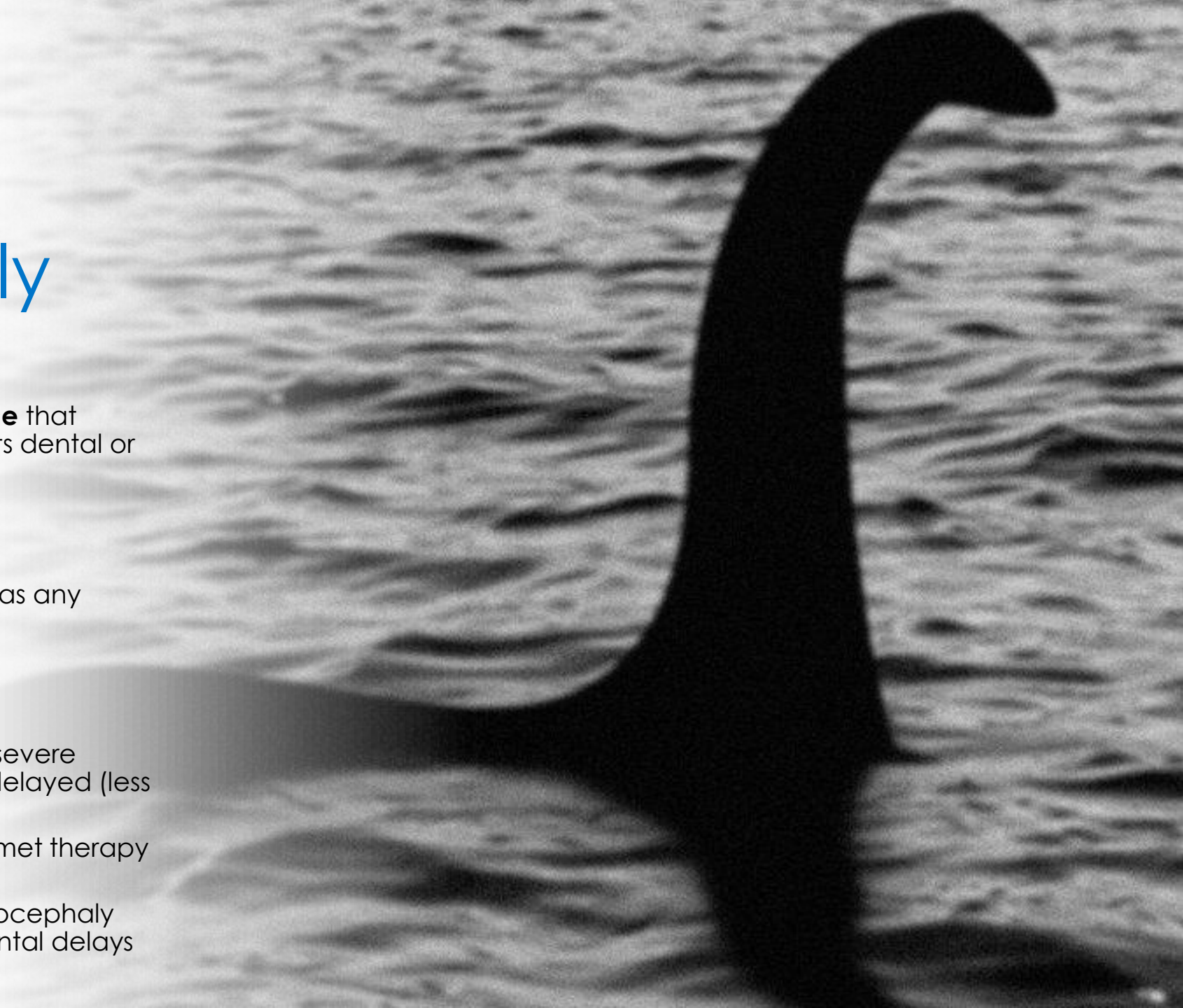
FIGURE 1 Differences in head shape from vertex view (arrows indicate directions of compensatory growth vectors). Positional molding produces parallelogram-shaped head (a). Unilateral lambdoid synostosis produces trapezoid-shaped head (b). (Reproduced from Huang et al., 1996).

Prognosis in Positional Plagiocephaly

- In most cases, excellent
 - Meeting gross motor milestones = less time on back of the head
- Regardless of treatment...
 - All children improve over time
 - No significant cosmetic issues by 3-5 years of age
 - Presenting severity determines outcome
- What can parents do?
 - Avoid having pressure on the back of the head
 - Repositioning during sleep
 - Extended tummy time
 - Minimizing time awake lying flat
 - Physical therapy for torticollis

Tall Tales Told in Positional Plagiocephaly

- Causes dental/jaw problems?
 - May be associated, but **no evidence** that helmet/conservative therapy affects dental or jaw development
- Causes sleep apnea?
 - **No evidence** that helmet therapy has any impact
- Causes neurodevelopmental problems?
 - Increased risk of having moderate/severe plagiocephaly if developmentally delayed (less mobility)
 - **No evidence** that conservative/helmet therapy lowers risk of developmental delays
 - Infants with moderate/severe plagiocephaly should be screened for developmental delays



Mild positional plagiocephaly

- Managed by PCP
 - Active repositioning
 - Increasing “tummy time”
 - Physical therapy

Moderate to Severe plagiocephaly

- Start with same conservative measures
- Consider helmet therapy if
 - Minimal/no improvement with conservative treatment
 - Requires continued supine positioning due to medical condition
 - Developmental delays
- No surgery needed



Helmet Therapy for Plagiocephaly

- Prevents ongoing pressure being placed on the flat side(s) of the head
 - Moderate to severe plagiocephaly
- Shown to improve the flattening faster when compared to repositioning and physical therapy alone
- More effective for plagiocephaly than brachycephaly
- 23 hours daily for 4-6 months
 - Requires frequent visits to orthotist for adjustments
 - Costs \$1,500-\$4,000
 - Must be removed in illnesses associated with fevers
 - Skin irritation

Helmet Therapy

- Redirects skull growth—requires growing skull!
- **Age** at the start of treatment and **severity** affect the duration and effectiveness of helmet therapy
- Success is determined by these two factors

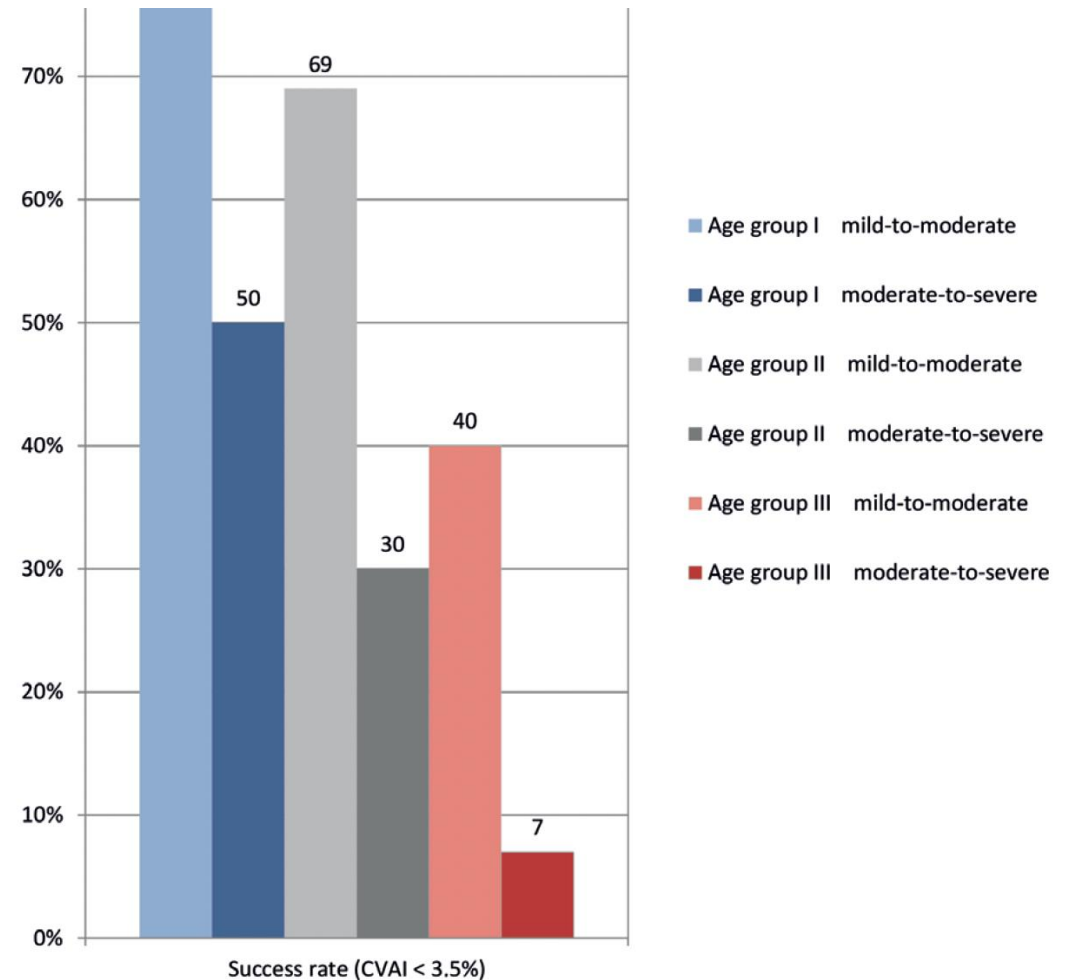
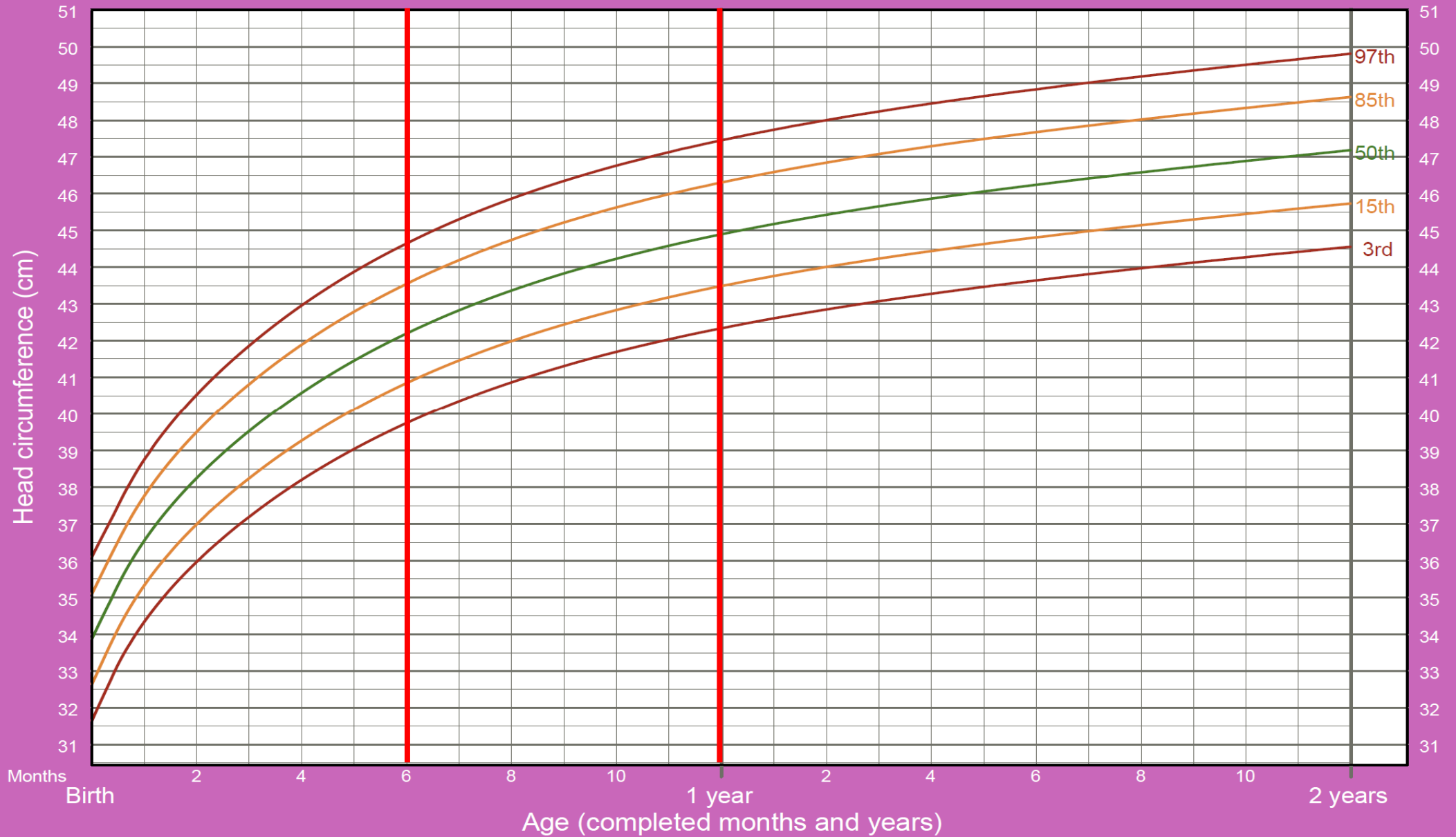


Fig. 6. Success rates (30-degree cranial vault asymmetry index <3.5 percent) of helmet therapy for all age and severity subgroups. CVAI, cranial vault asymmetry index.



So...do I need a helmet?

- **No clear evidence that helmet therapy is superior to conservative treatment in long term for most patients**
 - HEADS trial
 - Term infants 5-6 months of age with moderate to severe plagiocephaly without torticollis randomly assigned to helmet therapy vs conservative measures
 - No difference at 2 years of age



Head Shape Program at Children's Wisconsin

- Multidisciplinary program providing comprehensive care for children with head shape concerns
 - Neurosurgery
 - Plastic Surgery
 - Neuropsychology
 - Genetics
 - Neuroradiology
 - CW Audio Visual Services
 - *Hanger—orthotics
 - Physical Therapy—coming soon
- Launched January 2023



Head Shape Program

- Program is for patients with head SHAPE concerns
 - Craniosynostosis
 - Positional plagiocephaly (Moderate/Severe)
 - Abnormal head shape but unclear diagnosis
- Not for patients with head SIZE concerns
 - Microcephaly → Neurology
 - Macrocephaly → Neurosurgery

Referrals

- Internal referral to Head Shape Clinic
- If concerns for both head shape and head size, two referrals needed
 - Head Shape Clinic AND
 - Neurology (microcephaly) or Neurosurgery (macrocephaly) as appropriate

Ambulatory referral to Head Shape Clinic ✔ Accept ✖ Cancel

Process Instructions: A referral to Neurology is needed for Microcephaly or small head.
A referral to Neurosurgery is needed for Macrocephaly or large head.

Class: External Referral **Internal Referral**

Referral: Override Restrictions

To Department:

To Department Specialty:

To Provider:

Reason: Consultation/Treat Consultation/Treat Consultation Only Jointly manage care
Transfer of Care

Priority: Routine Routine Urgent Elective

Is patient being referred for the following

Small head/Microcephaly Large head/Macrocephaly Abnormal Head Shape Craniosynostosis

Plagiocephaly Other

ⓘ Please provide a brief description of head shape

ⓘ Has the patient had any imaging (CT, Xray, etc.)?
 Yes No

ⓘ Has the patient already been evaluated by or pending evaluation for a helmet (i.e., by Cranial Technologies, Hanger, etc.) (Note: An evaluation is not required prior to referral or visit.)?
 Yes No

ⓘ Is this a second opinion from Plastic Surgery or Neurosurgery?
 Yes No

ⓘ Referral Question (limit 200 char):

Appointments - Internal Referral (Stage 1 form)

Process/Instructions:

- is referral to Neurology is needed for Microcephaly or small head.
- is referral to Neurology is needed for Macrocephaly or large head.

Class: External Referral Internal Referral

Referral:

- Create Referrals
- To Department:
- To Department Specialty:
- to consider:

! Please provide a brief description of head shape

is gross motor milestone not meeting

Small head/Microcephaly
 Large head/Macrocephaly
 Abnormal head shape
 Concerns/other

Flagging/other Other

! Please provide a brief description of head shape

! How frequent feeding regimens (24 hrs old)?

Yes No

! How frequent sleep/feeding regimens by or pending evaluation for a habit (ie, behavioral techniques, naps, etc.) (enter an evaluation is not required prior to referral or visit)?

Yes No

! Is the current opinion from head surgery or neurosurgery?

Yes No

! History/Questionnaire (M-F)

Referrals

- External referrals
 - External referral order to CHW NEUROSURGERY
 - Please put Head Shape Clinic or abnormal head shape in comments

OR

- Fax referral for Head Shape clinic to Central Scheduling
 - (414) 607-5288



Children's
Wisconsin



Children's Specialty Group

Recap

- Craniosynostosis is relatively uncommon
 - Diagnosed on physical exam—consider skull XR if unclear
 - Almost never emergent, but timely referral important
- Positional plagiocephaly is very common
 - Aesthetic condition due to prolonged supine positioning
 - Mild—Conservative measures by PCP
 - Moderate to severe—Helmet therapy
 - Most effective if started before 8 months
- New Head Shape Program at Children's Wisconsin
 - Comprehensive multidisciplinary care

Thank You

- Head Shape Program

- Phone: **(414) 337-HEAD (4323)**
- E-mail: headshape@mcw.edu
- Fax: (414) 955-0243 to send medical records, notes, etc.

- Central Scheduling

- Phone: (877) 607-5280
- Fax: (414) 607-5288 to send external referrals



References

- Boran P, Oğuz F, Furman A, Sakarya S. Evaluation of fontanel size variation and closure time in children followed up from birth to 24 months. *J Neurosurg Pediatr.* 2018 Sep;22(3):323-329.
- Dias MS, Samson T, Rizk EB, Governale LS, Richtsmeier JT. Identifying the Misshapen Head: Craniosynostosis and Related Disorders. *Pediatrics.* 2020 Sep;146(3):e2020015511.
- Ghizoni E, Denadai R, Raposo-Amaral CA, Joaquim AF, Tedeschi H, Raposo-Amaral CE. Diagnosis of infant synostotic and nonsynostotic cranial deformities: a review for pediatricians. *Rev Paul Pediatr.* 2016 Dec;34(4):495-502.
- Graham T, Adams-Huet B, Gilbert N, Witthoff K, Gregory T, Walsh M. Effects of Initial Age and Severity on Cranial Remolding Orthotic Treatment for Infants with Deformational Plagiocephaly. *J Clin Med.* 2019 Jul 24;8(8):1097.
- Hersh DS, Bookland MJ, Hughes CD. Diagnosis and management of suture-related concerns of the infant skull. *Pediatr Clin North Am.* 2021 Aug;68(4):727-742.
- Hersh DS, Hughes CD. Syndromic Craniosynostosis: Unique Management Considerations. *Neurosurg Clin N Am.* 2022 Jan;33(1):105-112.
- Kiesler J, Ricer R. The abnormal fontanel. *Am Fam Physician.* 2003 Jun 15;67(12):2547-52.
- Kim MJ, Kang MK, Deslivia MF, Kim YO, Choi JW. Applicative Factors of Helmet Molding Therapy in Late-diagnosed Positional Plagiocephaly. *J Korean Med Sci.* 2020 Sep 14;35(36):e295.
- Morris LM. Nonsyndromic Craniosynostosis and Deformational Head Shape Disorders. *Facial Plast Surg Clin North Am.* 2016 Nov;24(4):517-530.
- Pindrik J, Ye X, Ji BG, Pendleton C, Ahn ES. Anterior fontanelle closure and size in full-term children based on head computed tomography. *Clin Pediatr (Phila).* 2014 Oct;53(12):1149-57.
- Pogliani L, Mameli C, Fabiano V, Zuccotti GV. Positional plagiocephaly: what the pediatrician needs to know. A review. *Childs Nerv Syst.* 2011 Nov;27(11):1867-76.
- Proctor MR, Meara JG. A review of the management of single-suture craniosynostosis, past, present, and future. *J Neurosurg Pediatr.* 2019 Dec 1;24(6):622-631.
- van Wijk RM, van Vlimmeren LA, Groothuis-Oudshoorn CG, Van der Ploeg CP, Ijzerman MJ, Boere-Boonekamp MM. Helmet therapy in infants with positional skull deformation: randomised controlled trial. *BMJ.* 2014 May 1;348:g2741.
- <https://www.mayoclinic.org/medical-professionals/neurology-neurosurgery/news/minimally-invasive-surgery-for-craniosynostosis/mac-20438762>